Precision Rhinoplasty. Part I: The Role of Life-Size Photographs and Soft-Tissue Cephalometric Analysis

Bahman Guyuron, M.D.

Cleveland, Ohio

I describe a simple technique of full-scale life-size photography using marker/stickers and a ruler at the side of the face as an index for magnification. I also report a technique of soft-tissue cephalometric analysis that consists of some new proportions and some old angles and measurements. This technique will enable the plastic surgeon, even if not artistically inclined, to draw an aesthetically pleasing and very proportionate profile outline of the nose and measure the proportions of the front view on the majority of patients. The difference between the patient's nasal outline and the planned nasal definition is then measured and expressed in quarters of millimeters to give the surgeon a very precise numeric guide for surgery. This will help the plastic surgeon define the aesthetic goals very accurately and also might be helpful in detecting other facial disharmonies that might be influential in the outcome of the rhinoplasty. Using this technique of analysis, along with the prediction guidelines extrapolated from my study on soft-tissue response to surgical alteration, one can develop a fairly predictable approach to rhinoplasty.

Undoubtedly, one of the most critical steps in a successful rhinoplasty is the precise definition of the aesthetic goals. Over the last 6 years, I have adapted and refined the use of exact life-size photographs, which are analyzed in detail using soft-tissue cephalometric principles in order to provide me with precision planning expressed in as small a fraction as a quarter of a millimeter. In this paper I will discuss the techniques of life-size photography and soft-tissue cephalometric analysis, which are a combination of some old relations and proportions and some new measurements and angles, and the outcome of my cephalometric and anthropometric experience an 1619 life-size photographs. Guided by these proportions and soft-tissue cephalometric angles, and aided by the three templates particularly designed for the nasal bridge and nasal tip contour and chin, the surgeon, regardless of artistic capability, can design a fine outline of the desired aesthetically pleasing nasal profile and the alar base dimension. This, in reality, is a blueprint of the balanced nose for that given face, which is used in the operating room during a precision rhinoplasty.

Technique of Life-Size Photography

An easily removable sticker/marker that is used for precise enlargement of the photographs is placed both on the glabella and the inferior border of the orbital rim, located by palpation. A ruler is then placed at the level of the orbit, on the side of the face, on front-view photography, and at the level of the nasal bridge on profile photography in order to ensure accuracy of the enlargement. Front-view and profile photographs are then taken and enlarged to life size using these indices. A drafting film (Polydraft*) is placed over the photograph and fixed into position with tape, and the following steps are taken in order to analyze the life-size photographs.

Analysis of Life-Size Photographs

Front View

1. The midpoint of the distance between the medial canthi is marked. This defines the midline of the upper face. For significant upper facial asymmetry, the face should be analyzed differently, which is beyond the scope of this article.

* Teledyne National Tracing Paper, Indianapolis, Indiana.

From the Division of Plastic Surgery at Mount Sinai Hospital. Received for publication January 22, 1987; revised May 7, 1987.

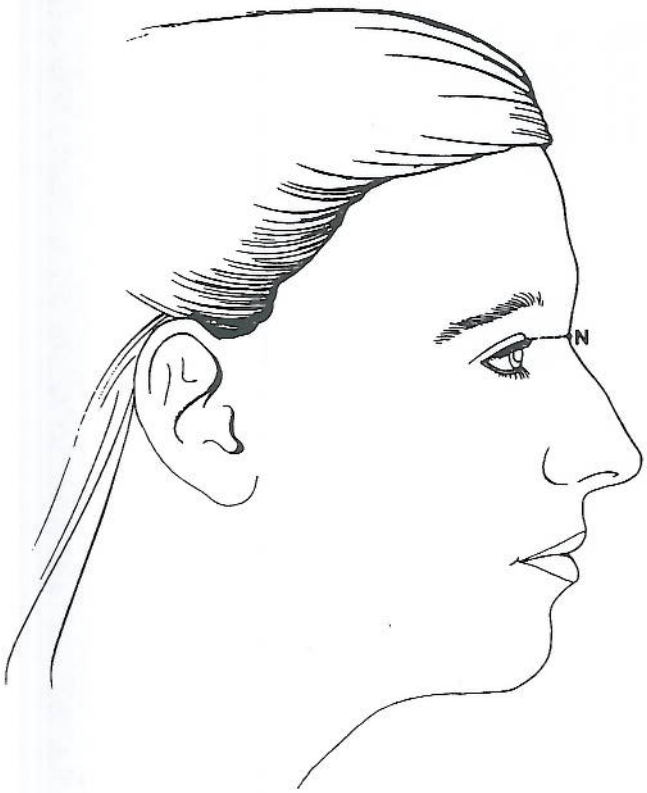

FIG. 1. The nasion, located at the deepest portion of the nasofrontal groove, is about 4 to 6 mm posterior to the glabella at the level of the margin of the upper lid.

2. If the remainder of the face looks symmetrical, the midpoint of the upper lip (philtrum dimple) will be marked as a lower face midline. Next, the upper and lower face midpoints are connected to define the vertical facial plane. The medial intercanthal distance is measured and compared to the eye fissure width. If these two measurements are equal, then two vertical lines are dropped parallel to the midfacial vertical plane. These two lines should pass about 1 to 2 mm medial to the outer margin of the alar base. If, however, the intercanthal distance is narrower or wider than the palpebral fissure width, then the latter will be used to judge the width of the alar base. The front-view analysis will reveal any nasal bridge or tip deviation and, more important, the alar base disproportions.

Profile

A drafting film is now placed over the profile life-size photograph.

1. The first step in analysis of the profile is to define the nasofrontal groove. The nasion (the deepest portion of the nasofrontal groove) is about 4 to 6 mm deep in relation to the glabella. If this groove is too shallow or too deep, the ideal point for the nasion is defined in the horizontal plane 4 to 6 mm deep and at the level of the lower border of the upper lid margin in a straight gaze (Fig. 1).

2. The upper border of the tragus is connected to the infra-orbital rim as marked before photography on the patient. This line is continued past the nasal outline (Frankfort horizontal plane) (Fig. 2, line F).

3. A line is dropped from the nasion in a 90-degree relation to the Frankfort horizontal line. This will define the vertical facial plane (Fig. 3, line *V*).

4. The most prominent portion of the tragus (tragion) is connected to the nasion (Fig. 4, line *TN*). According to my study, this line forms an angle of 69 degrees with the vertical facial plane. I use this line to ensure the proper position of the horizontal Frankfort plane.

5. From the nasion, the radix direction is drawn in a 34-degree angle for a female and a 36-degree angle for a male in relation to the vertical facial plane (Fig. 5, line R).

6. The distance between the nasion and the stomion (upper and lower lip junction) is measured and divided into three equal segments (Fig. 6).

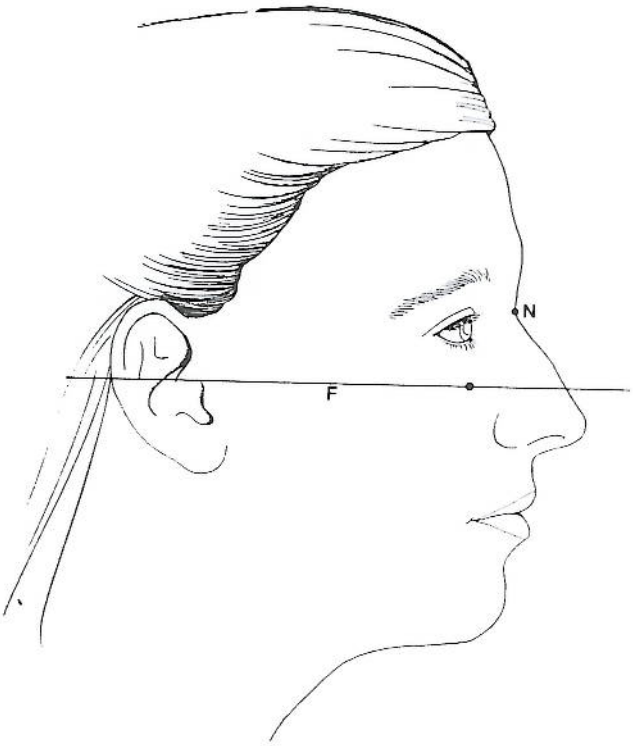

FIG. 2. The Frankfort horizontal plane is created by connecting the most prominent portion of the tragus to the nasion.

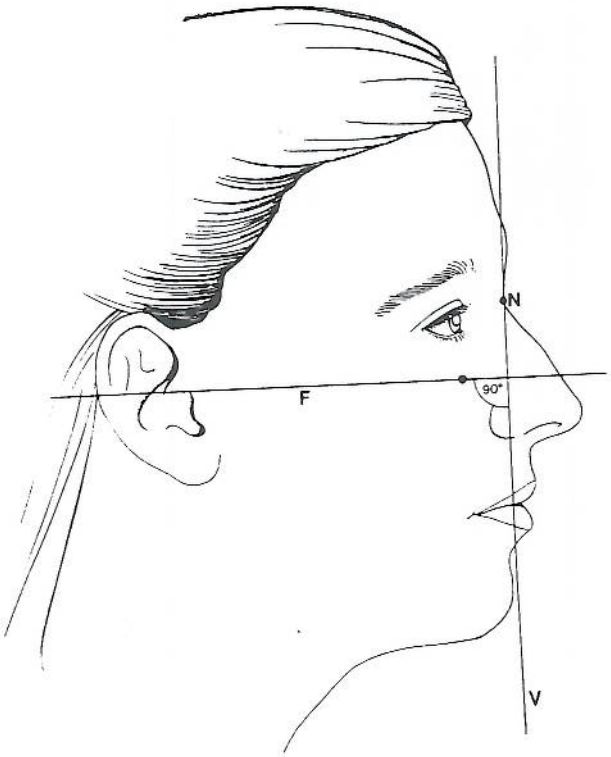

FIG. 3. A vertical line is dropped from the nasion to the Frankfort horizontal plane.

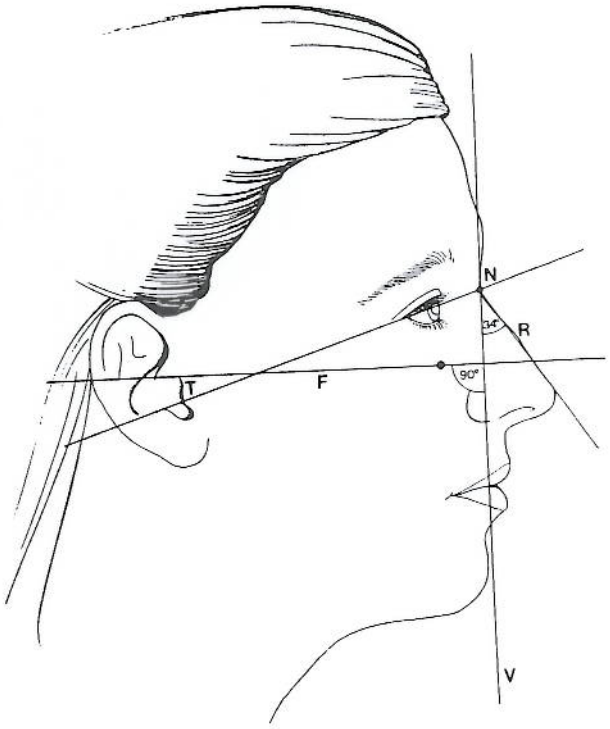

FIG. 5. The radix direction is drawn in a 34-degree angle for females and a 36-degree angle for males.

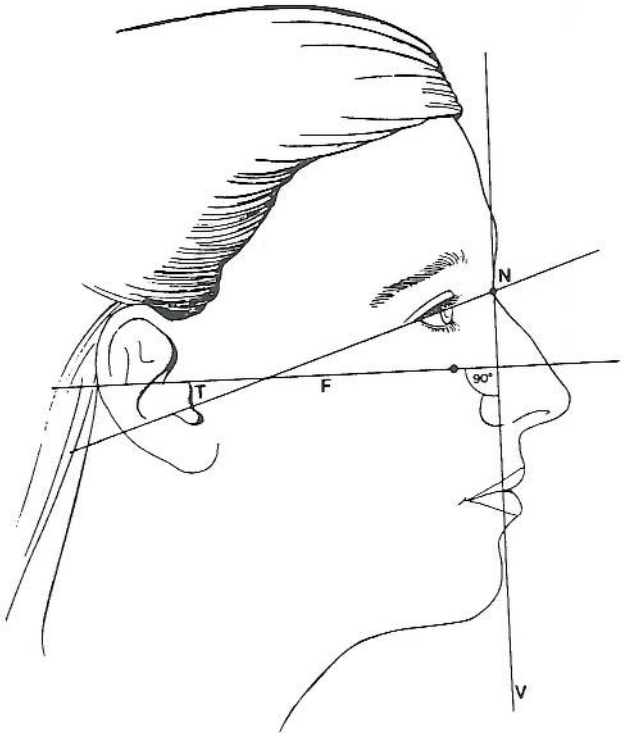

FIG. 4. The *TN* line is created by connecting the most prominent portion of the tragus to the nasion.

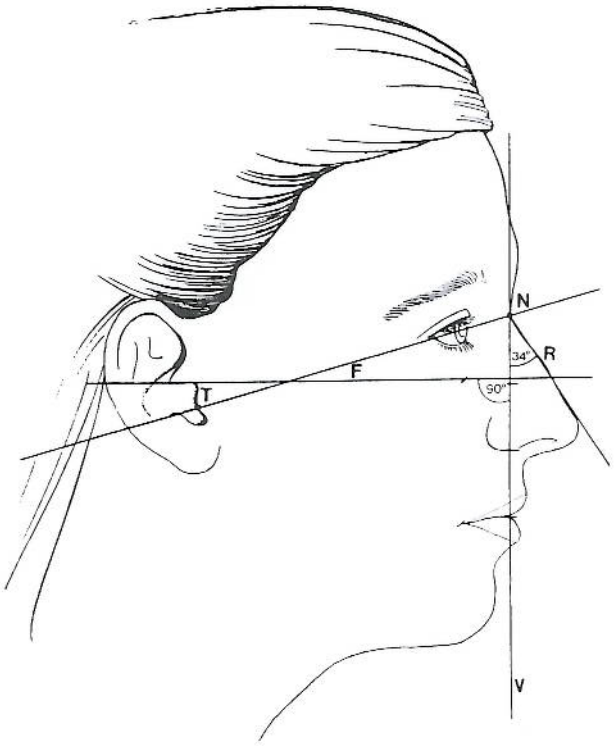

FIG. 6. The distance between the nasion and the stomion is divided into three equal parts.

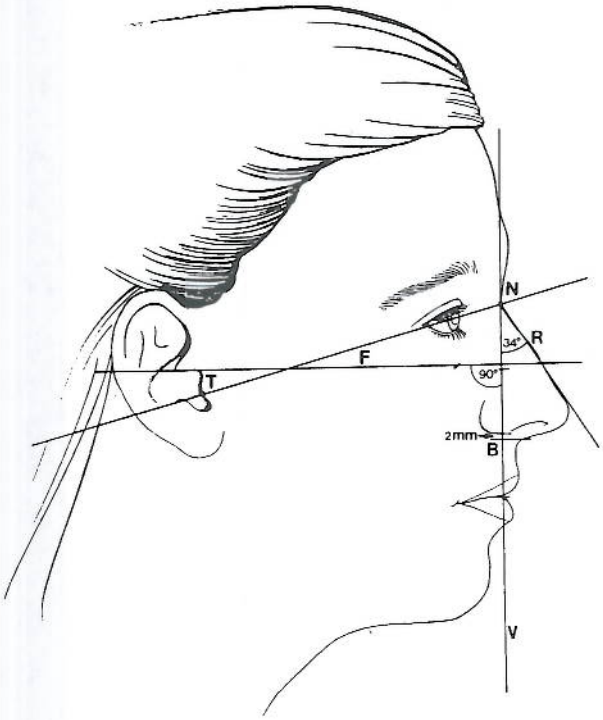

FIG. 7. A line is drawn parallel to the Frankfort horizontal facial plane at the junction of the upper two-thirds with the lower third of the distance from the nasion to the stomion.

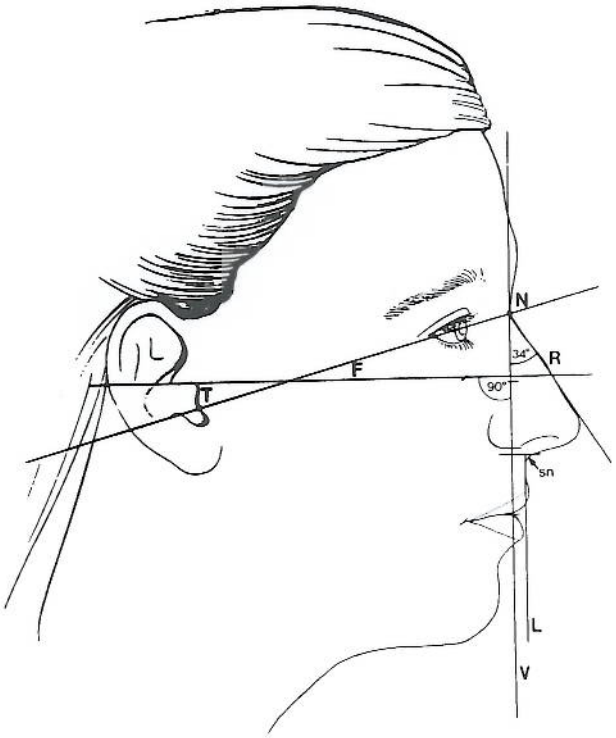

FIG. 8. A vertical line is drawn 1 to 2 mm behind the most prominent portion of the upper lip, parallel to the vertical facial plane.

7. A horizontal line is drawn parallel to the Frankfort horizontal facial plane 2 to 3 mm below the junction of the lower third with the upper two-thirds (Fig. 7, point *B*). This will outline the horizontal guide for locating the subnasale.

8. The most projected portion of the upper lip (labrale superius) is marked. A vertical line is drawn 1 to 2 mm behind this point parallel to the vertical facial plane (Fig. 8, line *L*). The subnasale is located at the point of intersection of this line with the previous horizontal line described in the preceding paragraph.

9. A line is projected from the subnasale in a 105- to 108-degree angle for a female and a 100- to 103-degree angle for a male in relation to the vertical line drawn in the preceding paragraph 8 in order to construct the nasolabial angle (Fig. 9). We now have a triangular nasal frame over which the nasal profile can be drawn with pleasing proportions.

10. The bridge template,* which has two different contours, one with a 0.75- to 1-mm-deep curve for a male nasal bridge and another with 1.5- to 2-mm depth for a female, is used to draw the bridge (Fig. 10).

* G.M. Plastics, 7252 Industrial Park Blvd., Mentor, Ohio 44060.

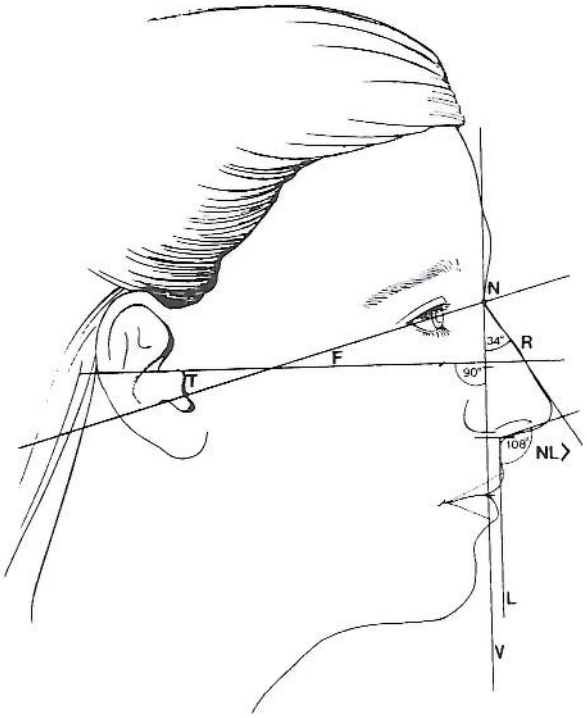

FIG. 9. The nasolabial angle is created by drawing a line in a 105-degree to 108-degree relation to the upper lip vertical line.

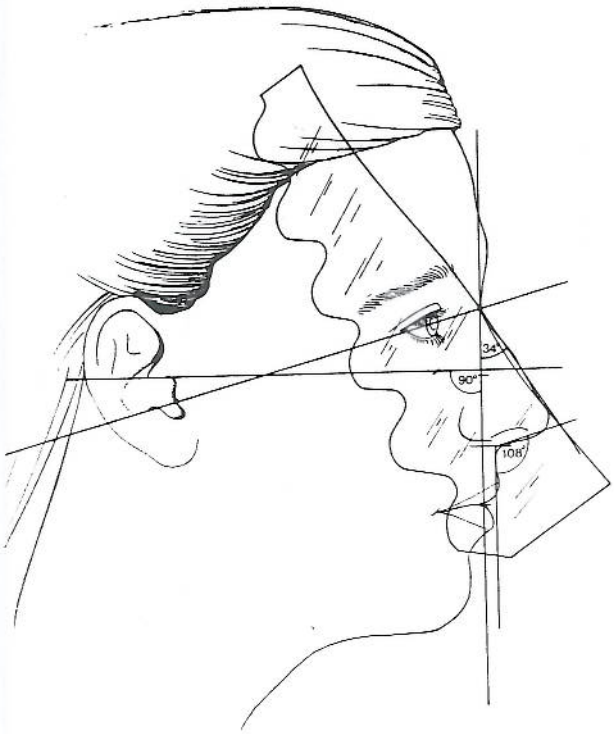

FIG. 10. The final bridge contour is drawn using a template.

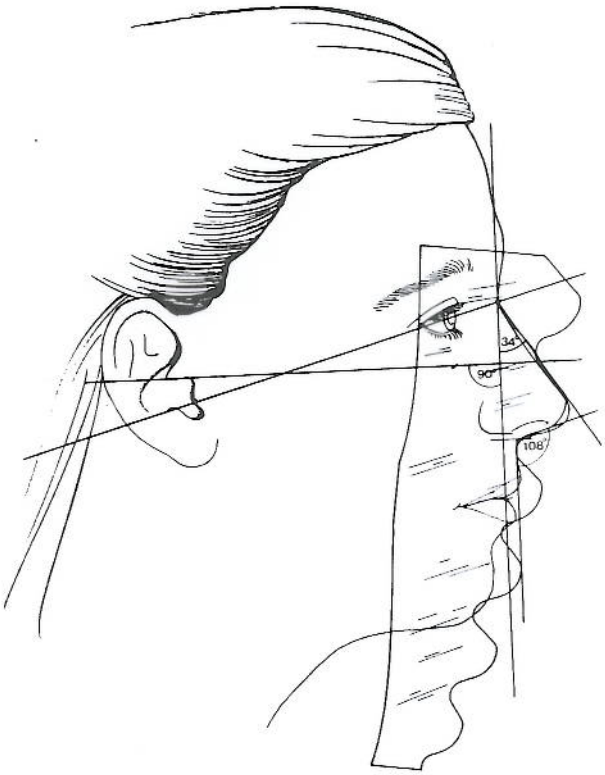

FIG. 11. The final design of the tip using a tip template.

11. A double-break tip-out line is then drawn using the multitip template (Fig. 11). By moving the template up and down, the proper tip size is chosen for the nose frame.

12. The most prominent portion of the upper lip is connected to the most prominent portion of the lower lip and continued. This line usually touches the most prominent portion of the chin (pogonion).[7] If the chin recedes, the second template (Fig. 12) is used to draw a proper labiomental groove and chin prominence. The labiomental groove is usually 3 to 4 mm deep on a female and 4 to 5 mm deep on a male.

DISCUSSION

Despite the earlier interest in soft-tissue cephalometrics,[2-4] the use of this helpful technique has not been popular. In 1979, Robin called our attention to the value of full-scale photography.[8] In my extensive review of the literature, this was the only article that dealt with the role of life-size photography in rhinoplasty. This article, however, suggests that the means by which these pictures are obtained and enlarged provides approximate full scale rather than precise. Furthermore, Robin uses his own artistic imagination to draw the ideal nose rather than using a scientific and cephalometric analysis, which yields a more

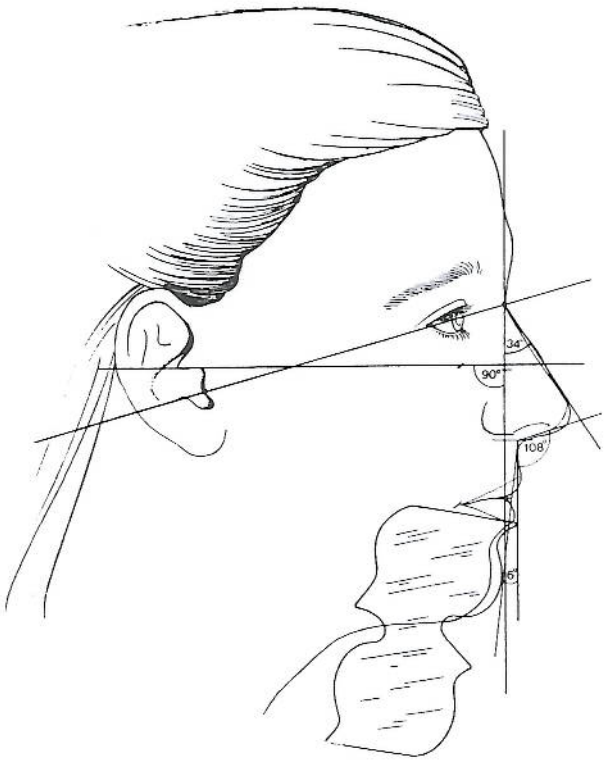

FIG. 12. The chin contour and labiomental groove are designed using a template.



FIG. 13. Photograph of actual templates.

proportionate nose and gives the plastic surgeon, who might not be artistically inclined, the ability to set the aesthetic goals with a precise definition.

My technique of life-size photography is a spin-off of craniofacial planning and experience.[9] This has evolved from the analyses of 1619 life-size photographs and soft-tissue cephalometrics. This large experience has enabled me to define some new proportions, lines, and values.

I feel that the nasofrontal relation is more of a groove than an angle, and according to my measurements, this ranges from 4 to 6 mm in depth. The depth of the nasofrontal groove is relative to the glabella, the deepest portion (nasion) being located at the lower margin of the upper lid in a straight gaze.

Measuring the alar base of the attractive face, in this study, revealed different data than was previously known. According to the available literature,[6] the intercanthal distance should be equal to the alar base distance. However, from my study of the attractive face, the total alar base is about 2 to 4 mm wider than the intercanthal distance. This, of course, is based on the assumption that the intercanthal distance is normal and equal to the palpebral fissure width. I chose the palpebral fissure width as a more reliable and applicable reference distance for the alar base.

One difficulty in soft-tissue analysis is locating the infraorbital rim on a profile photograph in order to define the horizontal facial plane. I have overcome this problem by first placing a marker, an easily removable sticker, on the infraorbital rim at the time of photography.[1] Second, I have measured the angle between the tragion-nasion line to the vertical facial plane using the cephaloxerograms that outline the infraorbital rim as well as the soft tissue clearly and concluded that in normal faces the angle between the tragion-nasion line and the vertical facial plane is about 67 to 73 degrees, with the mean being 69 degrees. This angle has a check value to ensure the accuracy of the horizontal and vertical facial planes.

There is a tendency to believe that the bridge of an aesthetically pleasing nose, particularly for

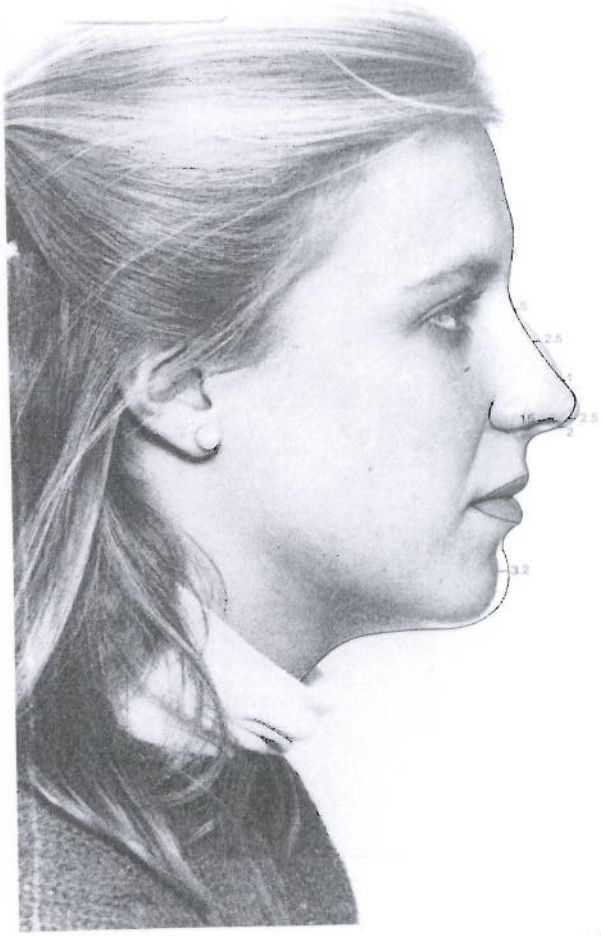

FIG. 14. The final outline of the proportionate nose for this patient defines the precise aesthetic goals in millimeters.

a male, is a straight line. In this study, I discovered that this was not true. There is indeed a gentle curve for both female and male bridge profiles; however, the male radix is about 0.75 to 1 mm deep and the female radix is 1.5 to 2 mm deep.

This extensive analysis also has enabled me to locate the subnasale by the method described in this article, which is one of the most important steps in drawing the lower nasal profile. This is usually located about 1 to 2 mm posterior to the most prominent portion of the upper lip and 2 to 3 mm below the junction of the lower third with the upper two-thirds, the distance from the nasion to the stomion.

My templates are also designed based on analysis of the above-mentioned life-size photographs on proportionate faces as judged by a plastic surgeon, a medical artist, and a photographer. The nasal tip templates were also made by grouping a variety of the shapes and sizes of the noses. These templates give the surgeon some flexibility in the range of the proper aesthetic proportions of the face and avoid having a prototype nose for everyone.

Advantages

This combined technique of exact life-size photography and cephalometric analysis has several advantages. It enables the surgeon to draw an outline of a balanced nose profile (Figs. 14, 16, 18, 20, and 22), regardless of artistic capability, and reveals any disharmony of the alar base. It defines the aesthetic goals very precisely and helps the surgeon to check the imperfections of the nose that would have possibly been missed otherwise. This technique allows the surgeon to review the whole face and recognize the other abnormalities that would have otherwise been overlooked. It is an excellent tool of review for the surgeon. By repeating the preoperative and postoperative life-size photographs (Figs. 15, 17, 19, 21, and 23) one can detect the imperfections in technique and learn to correct the problems faster than through the natural course.

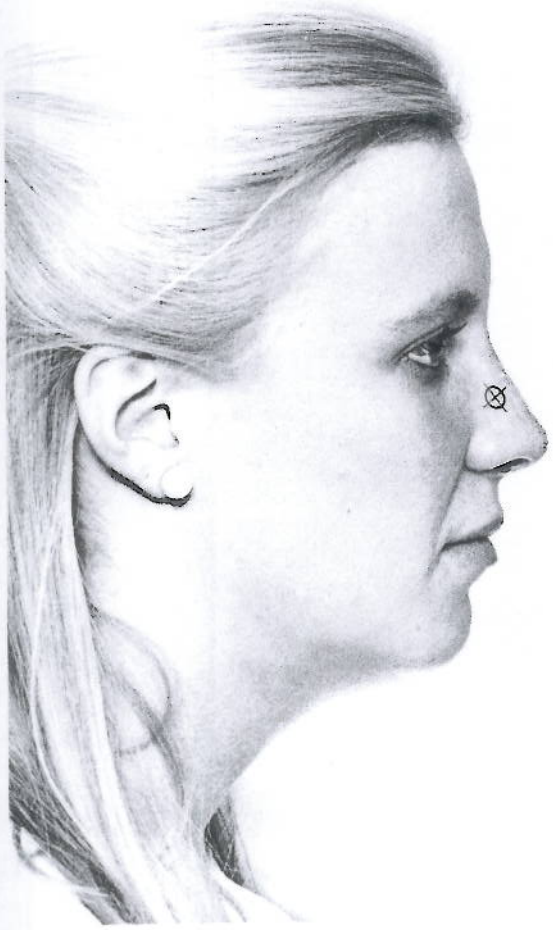

FIG. 15. Outcome of rhinoplasty on the same patient 1 year later.

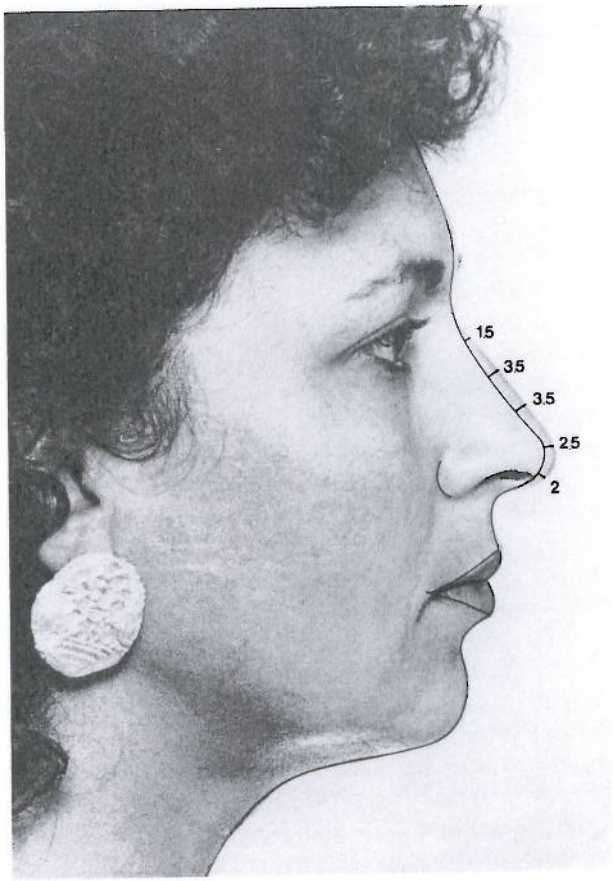

FIG. 16. Another example of precise preoperative planning.

FIG. 17. Postoperative photograph at 1½ years revealing the surgical outcome.

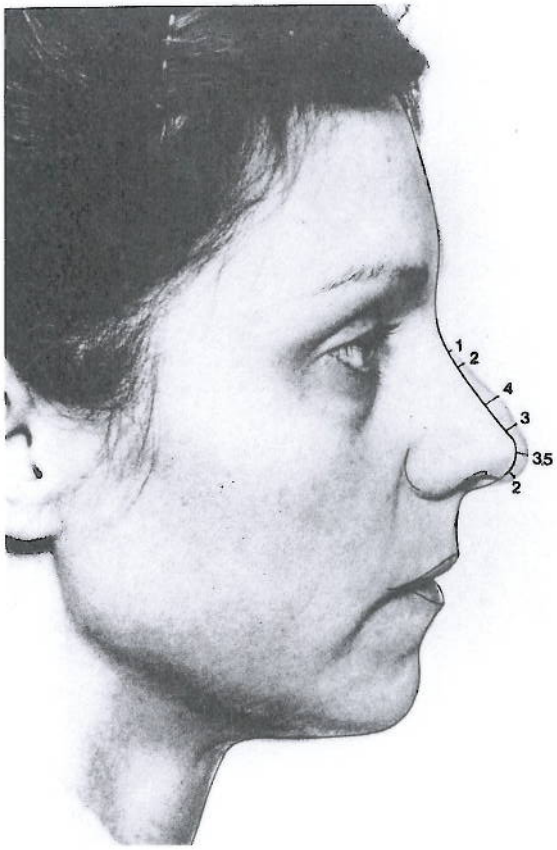

FIG. 18. Design of exact preoperative planning.

FIG. 19. Postoperative photograph at 2 years, illustrating the desired changes.

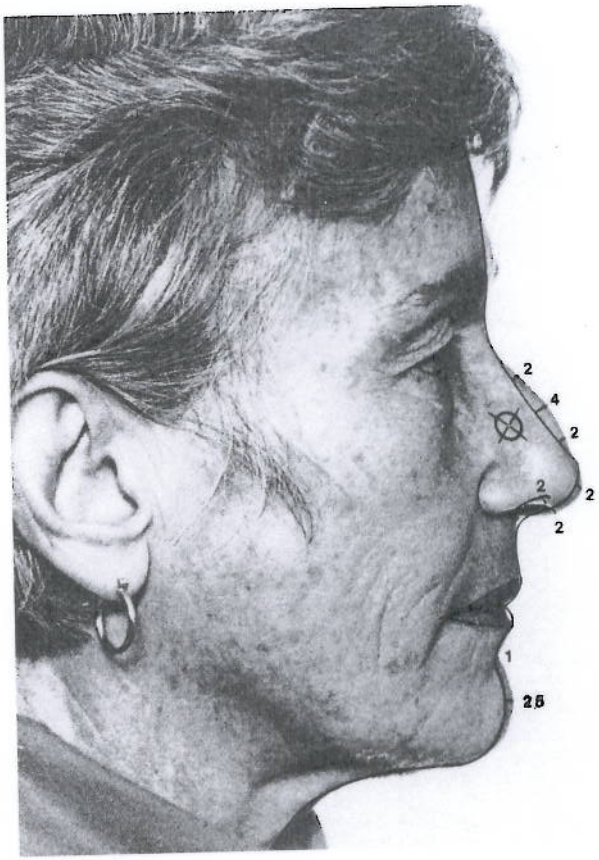

FIG. 20. Another patient before the surgery.

FIG. 21. Fourteen months following rhinoplasty.

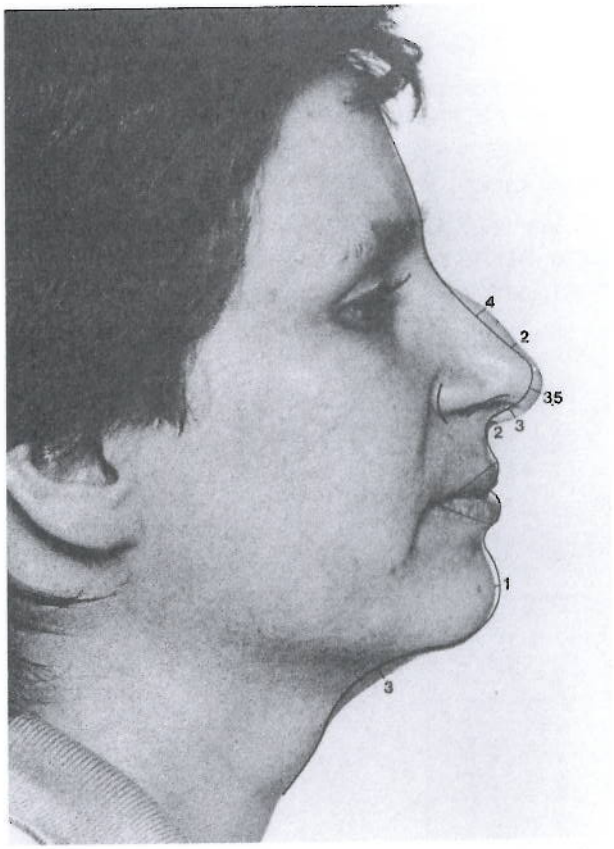

FIG. 22. Preoperative photograph reveals imbalance involving all the nasal units.

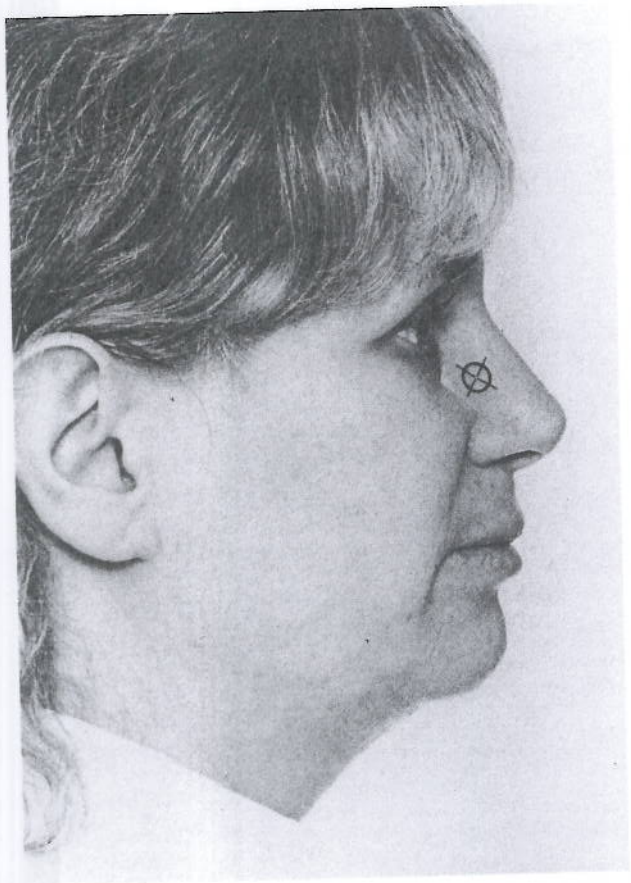

FIG. 23. Postoperative photograph 4 years later revealing proportionate/balanced nose.

Disadvantages

This technique requires a committed photographer to take time to ensure that the photographs are enlarged to the exact life size. Particularly, the initial few analyses are time-consuming. However, as experience is accumulated, the overall time required for soft-tissue analysis and the final drawing of the outline of the nose might not take more than 10 to 15 minutes.

Even though magnified projections of the routine slides can be analyzed using the same principles, they will not provide the surgeon with the same vision and control that the life-size photograph does, particularly in the operating room.

Bahman Guyuron, M.D.
29001 Cedar Road, Suite 406
Lyndhurst, Ohio 44124

ACKNOWLEDGMENTS

The author would like to express his appreciation for the assistance he received from Ms. Lorrie Willis in the method of collecting data and from Mr. Dan McGuirk in developing the templates and artwork.

REFERENCES

1. Daniel, R. K. Personal communications, 1987.
2. Gonzalez-Ulloa, M., and Stevens, E. The role of chin correction in profileplasty. *Plast. Reconstr. Surg.* 41: 477, 1968.
3. Gonzalez-Ulloa, M. Planning the integral correction of the human profile. *J. Int. Coll. Surg.* 36: 364, 1961.
4. Gonzalez-Ulloa, M. Quantitative principles in cosmetic surgery of the face (profileplasty). *Plast. Reconstr. Surg.* 29: 186, 1961.
5. Guyuron, B. Precision rhinoplasty. Part II: Prediction. *Plast. Reconstr. Surg.* 81: 5001, 1988.
6. Powell, N., and Humphreys, B. *Proportions of the Aesthetic Face.* New York: Thieme-Stratton, 1984.
7. Riedel, R. A. An analysis of the dentofacial relationships. *Am. J. Orthod.* 43: 103, 1957.
8. Robin, J.-L. The preplanned rhinoplasty. *Aesthet. Plast. Surg.* 3: 179, 1979.
9. Wright, A. Personal communications, 1987.